

A Study Evaluating Lid Reconstructive Surgeries

SOMASHEKAR P. BIRADAR, SHILPA S. BIRADAR, MANJUNATH KAMATH, GURUDUTT KAMATH

ABSTRACT

Background: Eyes are the most important aesthetic units in the human body. The increase in the number of patients who require reconstructive surgeries of the lid makes it imperative for the general ophthalmologists who have a limited experience in this field to acquire at least some knowledge about the basic principles of reconstructive surgeries.

Aim of the Study: To study and evaluate the basic principles of lid reconstructive surgeries.

Material and Methods: The study included 25 patients who attended the Department of Ophthalmology at KMC hospital, Mangalore. The study was conducted prospectively for a period

of 2 years. The patients who were included were those who were diagnosed to have Entropion, Ectropion, Ptosis and Lid tumours, in the age group of 10-69 yrs. After taking a brief history and after the clinical examination, the patients were operated. The pre-op, intra-op and post-op photographs were taken. Histopathological examination was done for concerned cases. The patients were followed up for 2 months.

Results: Our study included a total of 25 patients who underwent lid surgeries. The commonest was ectropion with 8 (32%) cases, followed by entropion, lid tumours and ptosis.

Conclusion: An attempt has been made to find out the effective surgeries for the various lid disorders.

Key Words: Ectropion, Entropion, Ptosis, Lid tumours and reconstructive surgeries

KEY MESSAGE

- A rise in the number of the lid disorders has been noticed.
- General ophthalmologists have limited experience in the basic principles and the practice of reconstruction surgery.
- It is imperative for the general ophthalmologists to acquire at least some knowledge about the basic principles of reconstructive surgeries.

INTRODUCTION

The objective of plastic surgery is the reconstruction of the anatomical and the functional defects in living tissues, as far as it is possible to do so. The ideal result of plastic surgery, should have an artistic quality and the shape and the lines of the features on both the sides of the face should be comparable [1].

Lid disorders requiring reconstructive surgeries:

Entropion: Lower eyelid involutinal entropion is a significant disorder of the aging population which results from horizontal eyelid laxity, an overriding orbicularis oculi muscle and the attenuation of the lower eyelid retractors. It is an inversion or turning inward of the lid margin [2].

Ectropion: It is an eversion or turning outward of the lid margin.

Ptosis: It is an abnormally low position (drooping) of the upper lid.

Lid tumours

Basic Principles for the Reconstruction of the eyelids:

The local anaesthetic which is used is adrenaline with 2% lignocaine, which helps in reducing oozing from the skin edges and it

also helps with local analgesia in the early post operative period. Any tissue handling must be gentle with blunt forceps.

All the skin incisions are marked with Bonny's blue (brilliant green and crystal violet paint BNF) to determine whether the proposed incision is correct. Wherever possible, the incisions should be placed in and parallel to the skinfolds and the hairline, as these heal well with minimal scarring. Haemostasis is generally carried out with the aid of a bipolar coagulator for the small bleeders and with the aid of a ligature for the large bleeders. The wounds are closed as far as possible without tension, to avoid skin necrosis.

The subcutaneous tissues are closed with absorbable sutures. The skin incision is closed accurately with the aid of interrupted or subcuticular sutures.

The skin suture line should not lie directly over the cartilage or the bone grafts, which must be covered completely with muscle or fascia before the skin closure to avoid extrusion of the graft. A minimum of dressings is required for incised wounds to absorb fluids and immobilise tissues. Skin grafts however, may require pressure dressing to maintain contact between graft and recipient bed.

The types of suturing:

The skin incisions are closed with the following types of sutures, thus making the incised edges everted and without tension.

- Interrupted sutures
- Continuous key pattern sutures
- Vertical mattress sutures
- Subcuticular stitches

The closure of the full thickness lid margin incision or wound: It is important to close the defect in layers, with particular attention being given to the precise coaptation of the lid margin to avoid lid notching.

The defects in the eyelid tissues are repaired by one or more of the following techniques.

1. Local flap:
 - Rotation flap
 - Transposition flap
 - Advancement flap
 - Island flap
2. Free grafts:
 - Skin grafts
 - Mucous membrane grafts
 - Fascia lata grafts
 - Expanded flaps [1]

The reconstruction of the eyelids is highly complex because of their function and their critical role in the appearance of the face. The optimal restoration of their form and function depends on a firm understanding of the normal eyelid position, the structural support system of the eyelids, and the forces that act to keep the eyelids in a precise balance. With this knowledge, the surgeon can choose from among numerous reconstructive techniques to correct a deficit, depending on its location, depth and size while restoring the normal eyelid function and an aesthetically pleasing form [1].

This article discusses the structural restoration options for the commonly encountered eyelid defects. However, not many studies have been carried out to know the effective reconstructive surgeries for the different lid disorders and hence this study was carried out.

MATERIAL AND METHODS

The present study was undertaken from April 2000 to Feb 2002 in the Department of Ophthalmology at the Government Wenlock Hospital and the K.M.C Hospital, Mangalore. The patients who were included were those who were diagnosed to have Entropion, Ectropion, Ptosis and Lid tumours, in the age group of 10-69 yrs. While planning for the reconstruction, the evaluation of the general state of the patient's health was done. For the local examination, a careful analysis of the defect was carried out.

The pre-operative, intra-operative and post-operative photographs were taken. A pre-operative evaluation on the type and the nature of the surgery was done and the patients were subjected to the concerned surgical procedures. A histopathological examination was done for the concerned cases. The patients were followed up for 2 months.

RESULTS

Our study included a total of 25 patients who underwent lid surgeries. The cases were distributed among all the age groups, the youngest being a child of 10 years and the oldest being a male

who was aged 69 years. A majority of them were males. Males accounted for 20 (80%) of the total 25 cases [Table/Fig-1].

Among the various lid disorders, ectropion was most commonly seen, with 8 (32%) cases, followed by entropion- 6 (24%), lid tumours- 6 (24%) and ptosis- 5 (20%) cases [Table/Fig-2].

The Modified Wheeler's operation was performed on six entropion cases which showed good results [Table/Fig-3 & 4]. The Lazy-T procedure was performed on 2 cases of senile medial ectropion. Horizontal lid shortening was performed on 4 cases. The Kuhnt-Szymanowski procedure was performed on 4 cases of severe senile ectropion with a redundant lower lid skin. A Frontalis Brow Suspension by using a prolene suture was performed on 3 cases of simple congenital ptosis, 1 case of neurogenic ptosis and on 1 case of traumatic ptosis with 3rd nerve palsy [Table/Fig-5 & 6].

Wide local excision and primary repair was done on 6 cases of various lid tumours [Table/Fig-7 & 8].

Surgical Techniques

The Modified Wheeler's Operation: It is indicated in cases of severe entropion [Table/Fig-4] with horizontal lid laxity. It involves partial tarsectomy (excision of a triangle of the tarsus, base down), overlapping two bands of the atonic orbicularis muscle and suturing these to a pleated orbital septum, thereby producing a bracing effect which corrects the entropion.

The Lazy-T Procedure: It is indicated to correct severe medial ectropion with an intact medial canthal tendon. It consists of a medial pentagonal full thickness excision of the lid tissue which is lateral to the inferior punctum, combined with medial conjunctivoplasty.

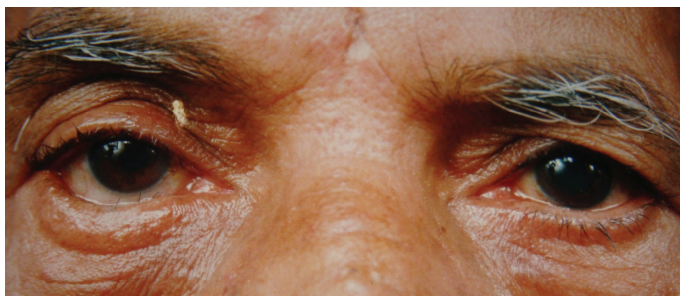Horizontal lid shortening: It involves the excision of a pentagon full thickness lid where the ectropion is maximal, with a significant correction of the medial or lateral canthal tendon laxity.

Age Group (years)	Male	Female	Total (percentage)
10-19	01	00	01 (4%)
20-29	03	01	04 (16%)
30-39	02	02	04 (16%)
40-49	03	02	05 (20%)
50-59	03	00	03 (16%)
60-69	05	03	08 (32%)
Total	17	08	25 (100%)

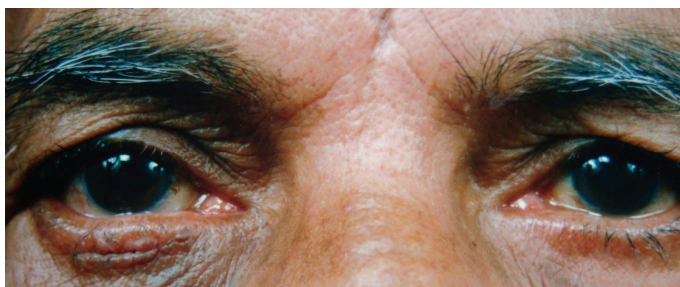[Table/Fig-1]: Age and sex distribution of the patients

Sl. No	Lid defects	No. of cases	Percentage
1	Entropion a) Senile Entropion	06	06(24%)
2	Ectropion a) Senile medial ectropion b) Severe senile ectropion c) Severe senile ectropion with redundant lower lid skin	02 04 02	08(32%)
3	Ptosis a) Simple Congenital Ptosis b) Neurogenic Ptosis c) Traumatic ptosis with 3rd nerve palsy	03 01 01	05(20%)
4	Lid Tumors a) Simple Dermoid cyst b) Meibomian gland carcinoma c) Plexiform Neurofibroma	03 02 01	06(24%)
	Total	25	100%

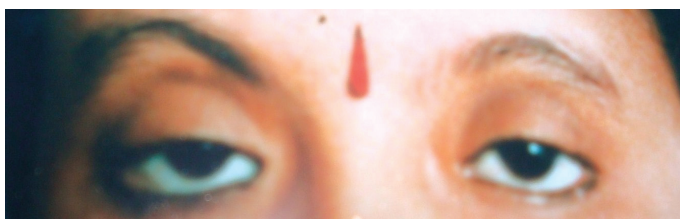[Table/Fig-2]: Lid defects



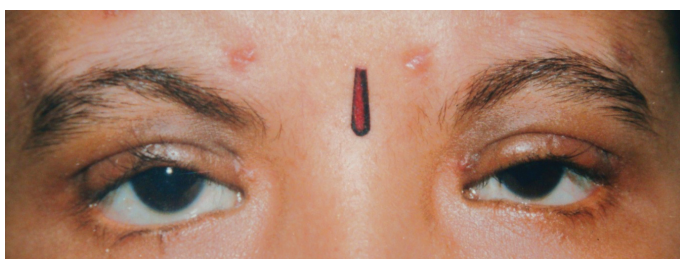[Table/Fig-3]: Pre-operative photograph with Senile Entropion right lower lid



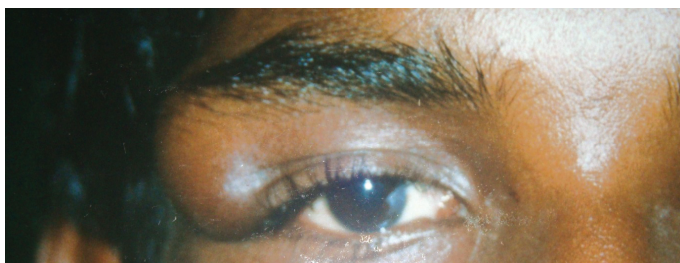
[Table/Fig-4]: Post operative photograph of the case with Senile Entropion right lower lid



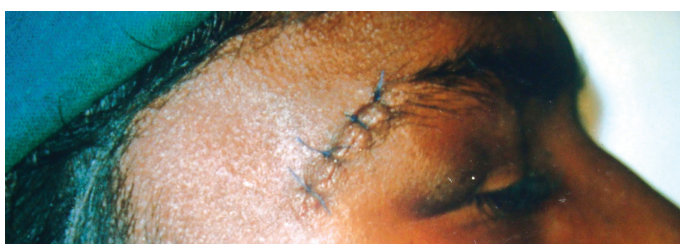[Table/Fig-5]: Pre-operative photograph Bilateral simple congenital ptosis



[Table/Fig-6]: Corrected by frontalis brow suspension



[Table/Fig-7]: Superficial Dermoid cyst of right upper lid



[Table/Fig-8]: Post operative photograph

The Kuhnt-Szymanowski Procedure: It is used for severe ectropion with a marked excess of the skin. It involves a pentagonal full thickness excision of the lid laterally and the excision of the lateral triangle redundant skin. If appropriate, canthal tendon tightening surgery is also done.

The Frontalis Brow-Suspension: The frontalis muscle normally lifts the eyebrow and contributes to lid elevation. This action is enhanced by connecting the frontalis muscle to the tarsus by using a subcutaneous sling which is made of various materials, which include:

- Autogenous Fascia lata, Palmaris longus tendon
- Synthetic materials like silicone, supramid and prolene

These procedures give symmetrical results if they are done on both the levators at the same sitting. In unilateral ptosis, the cosmetic appearance may not be that good [3].

DISCUSSION

A senile entropion is caused due to horizontal lid laxity and the overriding of the tarsus by the infratarsal tissues. It is corrected by producing a bracing effect for the lower lid by overlapping the orbicularis oculi band by using the Modified Wheeler's Operation.

In the present study, for 6 cases of senile entropion of the lower lid, the Modified Wheeler's Operation was performed and all the cases had satisfactory results, with no recurrences and under-correction. A study of senile entropion correction with Modified Wheeler's operation by Brack up All, had least recurrence rate. [4].

Another study reported entropion recurrence after a three-step transconjunctival repair. Recurrent entropion occurred in 3 of the 36 lower eyelids (8.3%). The recurrence was more frequent than that which was reported for a similar transcutaneous procedure [5].

In another study, the modified transconjunctival involucional lower eyelid entropion repair technique was performed on 114 eyelids of 89 consecutive patients, over a 7-year period. All the cases demonstrated the correction of the entropion at the 3-month follow-up [6].

One more study used a modified Quickert "4-snip" block excision, combined with lower eyelid retractor plication for central lower eyelid thinning with trichiasis [7].

Another study was carried out to evaluate the efficacy of the transconjunctival entropion repair (TCER) for a lower eyelid involucional entropion. This study which showed the surgical correction of the involucional entropion by the reinsertion of the lower eyelid retractors had a similar outcome with both the internal (transconjunctival) and the external (subciliary) approaches. Recurrence was higher with the internal approach (15% vs 3% with the subciliary incision), but this was not statistically significant [8].

A study which was conducted by Melanie H. Erb on transconjunctival entropion repair, resulted in the resolution of the entropion with a success rate of 96.7% (146 of 151 eyelids) the entropion recurrence rate was 3.3% (5 of 151 eyelids) [9].

A senile ectropion is caused due to the progressive stretching and the elongation of the lid margin and the canthal tendons. It is treated, depending on the position of the ectropion, the extent of the horizontal lid laxity and the severity of the canthal tendon laxity.

In the present study, for 4 cases of severe senile ectropion, horizontal lid shortening was done. For 2 cases of severe senile

ectropion of the lower lid with redundant lower lid skin, the Kuhnt's Szymanowski procedure was done and the results were satisfactory with no undercorrection or overcorrection.

For 2 cases of senile medial ectropion, the Lazy-T procedure was performed. The results were satisfactory in one case, but the other case had unsatisfactory results due to undercorrection.

A similar study on senile ectropion correction with horizontal lid shortening by Rees TD had achieved satisfactory results [10].

Any ptosis with poor levator function is mainly treated by the Frontalis Sling procedure. In the present study, for 3 cases of bilateral simple congenital ptosis and 2 cases of unilateral traumatic ptosis with poor levator function, the Frontalis suspension was performed by using the Prolene 4-0 sutures.

Satisfactory lid elevation was achieved in all cases except two. One case of simple congenital ptosis and one case of traumatic ptosis had unsatisfactory results due to overcorrection and a second operation was necessary to correct it. But the major drawback of the procedure was lid lag in the extreme down gaze.

In a similar study by Morax-S, Daendoin-F [11] of post-traumatic ptosis correction by using the Frontalis suspension achieved satisfactory cosmetic results and also in a study of 50 cases of simple congenital ptosis, correction by using the Frontalis suspension by Broughton WL and Mathews JG et al achieved satisfactory cosmetic and functional results [12].

Another study used a simplified technique for ptosis repair by using a single adjustable suture of blepharoptosis repair. This technique was aimed mainly towards mild or moderate ptosis. A satisfactory cosmetic result was achieved in all the cases [13].

Meibomian gland carcinoma of the upper lid is a lethal neoplasm, accounting for less than 1% of all the lid tumours. It is surgically treated by wide local excision and primary repair.

In the present study, for 2 cases of meibomian gland carcinoma of the upper lid with no regional metastasis, wide local excision and direct primary closure of the wound was performed. The results were satisfactory, with no recurrence of the tumour and the lid deformity.

In a similar study of 40 cases of meibomian gland carcinoma by Doxanas MT, Green-WR, wide local excision with primary repair was done and this showed satisfactory results with no tumour recurrence [14].

Another study used the reverse modified Hughes procedure with orbicularis muscle mobilization, which was successful in repairing extensive full-thickness upper eyelid defects (greater than 80% of the eyelid width), which were caused by tumours. The mobilization of the orbicularis oculi muscle, with its robust vascular supply, enhances the viability and the cosmetic appearance of the reconstructed eyelid. The complications included epithelial keratopathy, lagophthalmos, upper eyelid entropion, granuloma formation and lower eyelid entropion [15].

In one more study, the Sandwich technique by using an orbicularis oculi muscle advancement flap was performed for full-thickness lower eyelid defects after the tumour excision. The complications included ectropion or lid retraction, granuloma and notching [16].

For 4 cases of superficial dermoid cyst of the upper lid, excision and direct primary closure were performed and the results were satisfactory with no complications.

For 1 case of plexiform neurofibroma of the upper lid, excision and direct primary closure were performed with good cosmetic results.

CONCLUSION

The Modified Wheelers Operation is a technically simple and an effective surgical procedure for senile entropion.

Horizontal lid shortening is an effective method for the correction of severe senile ectropion.

The Frontalis Brow Suspension by using Prolene suture material is a simple, successful and cost effective procedure for ptosis with poor levator function.

For lid tumors, wide excision with direct primary closure is an effective procedure for the closure of up to one fourth full thickness upper lid marginal defects.

REFERENCES

- [1] MJ Roper Hall. Stallard's Eye Surgery, 7th ed. Butterworth. London: 1989:67-123.
- [2] Kanski J.J. *Clinical Ophthalmology*. 4th ed. Butterworth Heineman. Woburn:1999:12-40
- [3] Jenny J. Danks, Geoffery. R. Rose, *Ophthalmology*. 1998-105(11): 2065-67.
- [4] Bracken et al., Modified Wheeler Orbicularis overlap procedure for senile entropion :*Ophthalmic-Surg*.1979 Jun;10(6): 35-40.
- [5] Todd Cook , Mark J. Lucarelli , Bradley N. Lemke , Richard K. Dortzbach Primary and secondary transconjunctival involutional entropion repair. *Ophthalmology*. 2001;108(5): 989-993 .
- [6] Shawn J. Khan, Dale R. Meyer. Transconjunctival lower eyelid involutional entropion repair: Long-term follow-up and efficacy. *Ophthalmology*, 2002;109(11):2112-2117.
- [7] Mills, David M, Meyer, Dale R. Central lower eyelid thinning with trichiasis: Characterization and management of a unique subset of entropion in elderly patients. *Ophthal Plast Reconstr*. 2009; 25(6): 445-449.
- [8] Guy J. Ben Simon, Margarita Molina, Robert M. Schwarcz, John D. McCann et al. External (subciliary) vs internal (transconjunctival) involutional entropion repair. *Am J Ophthalmol*. 2005;139(3):482-487
- [9] Melanie H. Erb, Nicolas Uzcategui, Steven C. Dresner. Efficacy and Complications of the Transconjunctival Entropion Repair for Lower Eyelid *Involutional Entropion Ophthalmology*. 2006 December; 113(12):2351-2356.
- [10] Rees T.D. Prevention of ectropion by horizontal shortening of lower lid during blepharoplasty: *Ann Plast Surg* 1983;11(1):17-23
- [11] Morax S. Daudoin F. et al. Surgery of post traumatic ptosis. *Aun Chir Plast Esthet* 1995 Dec; 40(6):1691-705.
- [12] Broughton W.L. Mathews JG et al. Congenital ptosis. Results of treatment using lyophilised fascia lata for frontalis suspension. *Ophthalmology* 1982 Nov; 89(11):1261-6.
- [13] Murray A. Meltzer, Ebrahim Elahi, Paul Taupeka and Elsa Flores- A simplified technique of ptosis repair using a single adjustable suture *Ophthalmology*. 2001;108(10):1889-1892.
- [14] Doxanas MT: Green WR .Sebaceous gland carcinoma. Review of 40 cases. *Arch Ophthalmol* 1984 Feb;102(2): 245-9.
- [15] Sa, Ho-Seok, In Woo, Kyung, Kim, Yoon-Duck. Reverse Modified Hughes procedure for upper eyelid reconstruction. *Ophthal Plast Reconstr*. 2010; 26(3):155-160.
- [16] Dion P, Willem A. van den B. Orbicularis Muscle Advancement Flap Combined with Free Posterior and Anterior Lamellar Grafts: A 1-Stage Sandwich Technique for Eyelid Reconstruction. *Ophthalmology*. 2008;115(1):189-194.

AUTHOR(S):

1. Dr. Somashekar P. Biradar
3. Dr. Shilpa S. Biradar
4. Dr. Manjunath Kamath
5. Dr. Gurudutt Kamath

PARTICULARS OF CONTRIBUTORS:

1. Assistant Professor in Dept of Ophthalmology, SN Medical College, Bagalkot, India.
2. Assistant Professor in Dept of Pathology, SN Medical College, Bagalkot, India.
3. Professor in Dept of Ophthalmology, KMC, Mangalore, India.
4. Professor and HOD of Dept of Ophthalmology, KMC, Mangalore, India.

NAME, ADDRESS, TELEPHONE, E-MAIL ID OF THE CORRESPONDING AUTHOR:

Dr Somashekar P. Biradar
C-13, Staff quarters, SN Medical College,
Bagalkot.587101. Karnataka.
Phone: 09945090687
E-mail: drsomubiradar@yahoo.co.in; shilpa.s.biradar@gmail.com

DECLARATION ON COMPETING INTERESTS:

No competing Interests.

Date of Submission: **Mar 30, 2011**
Date of Peer Review: **May 13, 2011**
Date of Acceptance: **Jun 01, 2011**
Online First: **Jul 05, 2011**
Date of Publishing: **Aug 08, 2011**